

Entrez PubMed

Nucleotide

Protein

Genome

Structure

OMIM

PMC

Journals

Books

Search PubMed

for

Go

Clear

Limits

Preview/Index

History

Clipboard

Details

Display

Abstract

Show: 20

Sort

Send to

Text

About Entrez

Text Version

 1: AJR Am J Roentgenol. 2004 Nov;183(5):1267-74.

Related Articles, Links

Entrez PubMed

Overview

Help | FAQ

Tutorial

New/Noteworthy

E-Utilities

PubMed Services

Journals Database

MeSH Database

Single Citation Matcher

Batch Citation Matcher

Clinical Queries

LinkOut

Cubby

Related Resources

Order Documents

NLM Catalog

NLM Gateway

TOXNET

Consumer Health

Clinical Alerts

ClinicalTrials.gov

PubMed Central

Pancreatic duct after pancreatoduodenectomy: morphologic and functional evaluation with secretin-stimulated MR pancreatography.

Monill J, Pernas J, Clavero J, Farre A, Morales A, Gonzalez M, Artigas V, Martinez-Noguera A.

Department of Radiology, Hospital de la Santa Creu i Sant Pau, Universitat Autònoma de Barcelona, Sant Antoni M. Claret 167, Barcelona 08025, Spain. jmonills@menta.net

OBJECTIVE: The purpose of this study was to evaluate the usefulness of secretin-enhanced MR pancreatography in evaluating morphologic changes and pancreatic function after pancreatoduodenectomy. **SUBJECTS AND METHODS:** Twenty patients who underwent pancreatoduodenectomy were evaluated with secretin MR pancreatography. Single-shot fast spin-echo T2-weighted dynamic MR pancreatograms were obtained before and every minute for 10 min after secretin injection. Image analysis included image quality for the visualization of the pancreatic duct and morphologic features of the pancreatic duct (side branches, ductal narrowing, irregular ductal contour, and patency of the anastomotic site). Pancreatic function was assessed using the Van de Kamer method and the fasting blood glucose and oral glucose tolerance tests. Jejunal filling was graded from the lowest amount of filling (grade 1) to normal filling (grade 3) on the last MR pancreatogram. **RESULTS:** The visualization of the main pancreatic duct was significantly improved with dynamic MR pancreatography ($p < 0.05$). The anastomotic site was visualized in 14 patients (70%) on MR pancreatography after secretin administration ($p < 0.05$). No statistically significant improvement in other morphologic data was seen after secretin administration. The sensitivity, specificity, positive predictive value, and negative predictive value of reduced jejunal filling (grade 1) for assessment of reduced pancreatic exocrine function were 92%, 71%, 85%, and 83%, respectively. The relation between reduced jejunal filling (grade 1) and diabetes was statistically significant ($p < 0.05$). **CONCLUSION:** The administration of secretin improves visualization of the pancreatic ducts and helps in the evaluation of remnant pancreatic function after pancreatoduodenectomy.

PMID: 15505290 [PubMed - indexed for MEDLINE]

Display

Abstract

Show: 20

Sort

Send to

Text

Write to the Help Desk
NCBI | NLM | NIH

INTRODUCTION

The most sensitive diagnostic modality in suspected biliopancreatic diseases is endoscopic retrograde cholangiopancreatography (ERCP)^[1-4]. However, the success rate of the examination mainly depends on the experience of the endoscopist, and does not exceed 95-98% even in the largest specialized centers. Previous operations (Billroth II, Roux-en-Y or biliary-enteric anatomy), duodenal stenosis, or duodenal diverticulum make cannulation of the ducts difficult or even impossible, and increase the risk of complications^[5-7]. If ERCP fails, intravenous (iv) or percutaneous transhepatic cholangiography (PTC) is the alternative method. Since the diagnostic accuracy of iv cholangiography is very low, it is no longer used. PTC is invasive, may be associated with severe complications, and can successfully be applied if the intrahepatic biliary tree is dilated. PTC and iv cholangiography are both unable to visualize the pancreatic duct^[8-10]. There is clearly a need for a noninvasive, sensitive and specific diagnostic modality for patients with suspected biliopancreatic disease if ERCP fails^[11]. Magnetic resonance cholangiopancreatography (MRCP) is a new noninvasive diagnostic modality capable of producing high-quality images of the pancreatobiliary tree. It has been emphasized that its sensitivity (81-100%), specificity (94-98%), positive (86-93%) and negative (94-98%) predictive values and diagnostic accuracy (94-97%) are as high as those of ERCP, which makes MRCP a promising alternative to diagnostic ERCP^[12-16]. Moreover, MRCP has the following advantages over ERCP. It is noninvasive, there are no complications, no radiation, no need for any contrast agent. It causes less discomfort for the patients, and can provide useful information on the parenchymatous organs in this region in combination with conventional cross-sectional MR sequences.

The aim of our study was to assess the value of MRCP in the management of patients with biliopancreatic diseases in whom ERCP was failed.

MATERIALS AND METHODS

Between January 2000 and June 2003 a prospective study was conducted. Twenty-two patients were enrolled, in whom ERCP performed by experts at our endoscopic unit failed to adequately visualize the clinically relevant duct(s). Failure meant two unsuccessful ERCP attempts by precut papillotomy with a needle knife when the ducts were not cannulated with the conventional approach. There were 10 males and 12 females, with a mean age of 51.2 years, range 24-82 years. The indications for ERCP were obstructive jaundice ($n = 9$), abnormal liver enzymes ($n =$

8), suspected chronic pancreatitis ($n = 2$), recurrent acute pancreatitis ($n = 2$), or suspected pancreatic cancer ($n = 1$). The reasons for the ERCP failure were the postsurgical anatomy ($n = 7$), duodenal stenosis ($n = 3$), duodenal diverticulum ($n = 2$), or technical failure ($n = 10$) (Table 1). All patients gave their informed consent after receiving a detailed explanation of the complete examination procedure.

MRCP

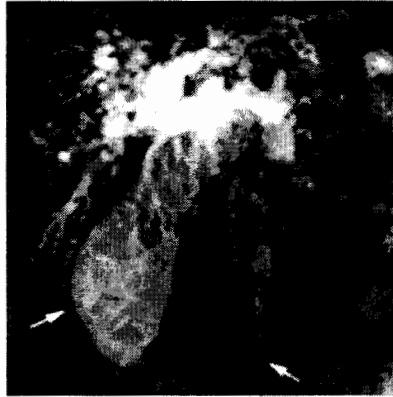
All patients underwent MR imaging (Signa Horizon LX 1.0 T-Scanner, General Electric, USA). T1-weighted and T2-weighted axial plane fast spoiled gradient (FSPGR) images were acquired. These images were used to evaluate the liver and pancreas parenchyma and also to plan the MRCP data collection. The heavily T2-weighted MRCP images were taken in two sets. With a single shot technique, one 30.0-70.0-mm-thick slice was first acquired at TR 5 000 ms, TE 500 ms, with a 320×320 matrix and 40×36 FOV. In the second set, 9-13 thin (5.0 mm) slices with a 2-mm gap were taken from the same region. The breath-hold technique was used for all sequences. "Dualflex" flexible body coil was applied. MRCP images were evaluated before and 5 and 10 min after the iv administration of 0.5 IU/kg secretin (Secretolin, Hoechst, Frankfurt am Main, Germany)^[17]. The administration of secretin induced the secretion of bile and pancreatic juice. Consequently, the ductal filling was increased, and the visualization of the biliary and pancreatic ducts and the image quality were therefore improved^[18].

RESULTS

The MRCP images were of diagnostic quality in all but 1 patient. MRCP furnished normal findings in 5 cases and revealed abnormalities in 17 patients (Table 1). Conservative medical treatment was applied in 10 cases. MRCP demonstrated mild bile duct dilation caused by chronic pancreatitis in 3 patients. Since they were mainly asymptomatic, surgical intervention was not indicated. Primary sclerosing cholangitis was indicated by MRCP in 3 patients, the cholestasis was improved after treatment with ursodeoxycholic acid. Gallbladder stones were found in an 82-year-old female patient, operation was not recommended because of her age. In a 77-year-old female patient who had previously undergone choledochoduodenostomy, the extrahepatic biliary tree exhibited caliber changes. This finding was considered to correspond to cholangitis, the abnormal liver function was normalized by antibiotic therapy. In 2 patients with previous

cholecystectomy and abnormal liver enzymes, MRCP revealed mild extrahepatic bile duct dilation (postcholecystectomy syndrome?). The liver function normalized without treatment in 1 patient, and in response to ursodeoxycholic acid treatment in the other (Table 1).

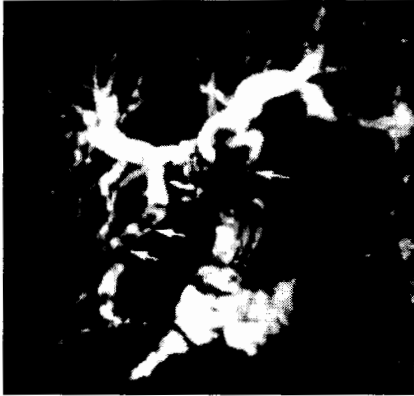Figure 1 MRCP of a 78-year-old female patient. The common bile duct is dilated with a stricture at the level of the papilla of Vateri (open arrow), with multiple stones in the gallbladder (solid



arrow). The Wirsung duct is not visible.

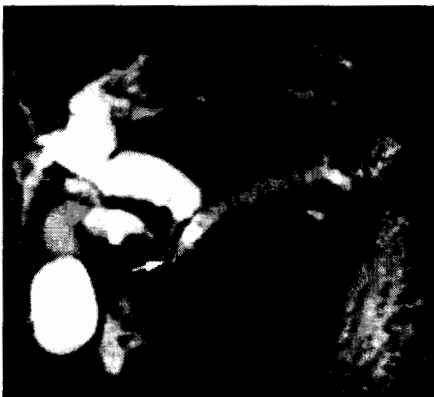Seven patients required therapeutic interventions. Four of these 7 patients underwent surgery. The indication for operation was based on the MRCP findings, which were confirmed at surgery in 3 of the 4 cases. In 1 patient (No. 10, Figure 1), MRCP revealed only the site, but not the cause of the bile duct obstruction. This patient was referred to the endoscopy unit because of obstructive jaundice. MRCP demonstrated a prepapillary common bile duct obstruction. The Wirsung duct was not visible. These findings, the clinical picture and the result of duodenoscopy led to a suspicion of pancreatic head carcinoma. The patient was operated on, and the surgery confirmed the suspicion. Curative resection was not possible because of the local invasiveness of the tumor, bilio-enteric anastomosis was performed.

Figure 2 MRCP of a 58-year-old female patient in whom ERCP failed because of a previous Billroth II resection. The intrahepatic biliary tree is markedly dilated with stones (open arrows), and the choledochojejunostomy anastomosis is narrowed (solid arrow). The patient underwent hepaticotomy and Kehr drainage.



In 1 patient in whom ERCP was failed because of a previous Billroth II resection, MRCP demonstrated a stricture of the choledochojejunostomy anastomosis as the cause of a bile duct obstruction (No. 1, Figure 2). The intrahepatic biliary tree was markedly dilated and contained secondary stones. The patient subsequently underwent hepaticotomy and Kehr drainage.

Figure 3 MRCP of a 63-year-old male patient in whom ERCP failed because of duodenal stenosis. The calcified pancreatic head obstructs the Wirsung duct and the common bile duct (arrow) with an upstream dilation, causing the "double duct sign". The intrahepatic biliary tree and the cystic duct are also dilated. The patient underwent choledochojejunostomy, gastrojejunostomy and Wirsungogastrostomy.



In a patient with chronic pancreatitis, whose disease was not followed up regularly, ERCP was indicated because of obstructive jaundice, but it failed in consequence of duodenal stenosis. MRCP showed obstruction of the Wirsung duct and the common bile duct by the calcified

pancreatic head, with an upstream dilation in both ducts, causing the "double duct sign" (No. 11, Figure 3). The intrahepatic biliary tree and the cystic duct were also dilated. The patient underwent choledochojejunostomy, gastrojejunostomy and Wirsungo gastrostomy. Similarly, in a patient with chronic pancreatitis in whom a previous Billroth II resection precluded ERCP, MRCP demonstrated an intrapancreatic bile duct obstruction. Choledochoenterostomy was performed (No. 19).

In 3 patients of advanced age in a moribund physical status, the bile duct obstruction was treated with percutaneous transhepatic drainage (PTD). MRCP indicated common bile duct stones in a patient who had previously undergone choledochojejunostomy (No. 3), another with a hepaticojejunostomy anastomotic stricture (No. 4) and one with prepapillary cholangiocarcinoma (No. 8, Figure 4). These findings were confirmed by PTC and the patients subsequently underwent biliary drainage.

Table 1 Indications for ERCP, reasons for ERCP failure, MRCP findings, and management of patients

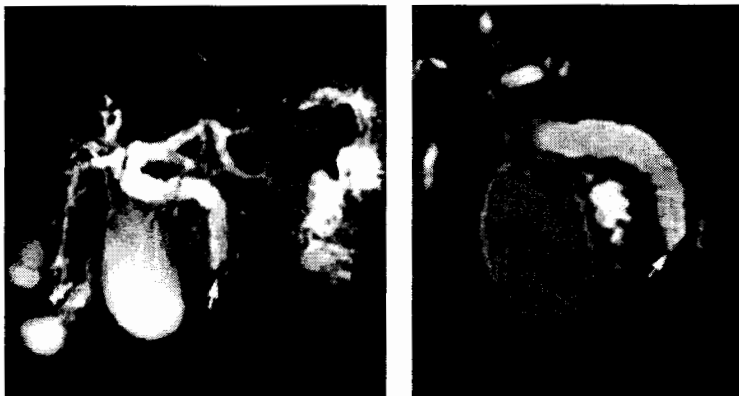Patient	Indication for ERCP	Reason for ERCP failure	MRCP findings	Management of patients
1	Obstructive jaundice	Billroth II anatomy (choledochojejunostomy anatomy)	stricture of choledochojejunostomy	hepaticotomy +Kehr drainage
2	Obstructive jaundice	Billroth II anatomy (choledochojejunostomy anatomy)	cholangitis	antibiotic treatment
3	Obstructive jaundice	choledochojejunostomy anatomy	choledocholithiasis	PTD
4	Obstructive jaundice	Roux and Y anatomy hepaticojejunostomy anatomy	stricture of hepaticojejunostomy	PTD
5	Cholestasis biliary pancreatitis	technical	cholecystolithiasis	follow-up
6	Cholestasis	technical	mild CBD dilatation	follow-up
7	Suspected pancreatic	duodenal stenosis	chronic pancreatitis	follow-up

	cancer			
8	Obstructive jaundice	technical	cholangiocarcinoma	PTD
9	Cholestasis	technical	PSC	follow-up
10	Obstructive jaundice	technical	distal stricture of CBD	hepaticojejunostomy unresectable pancreas carcinoma
11	Obstructive jaundice chronic pancreatitis	duodenal stenosis	"double duct sign"	choledochojejunostomy gastrojejunostomy Wirsungogastrostomy
12	Obstructive jaundice chronic pancreatitis	technical	intrapancreatic stricture of CBD, chronic pancreatitis	follow-up
13	Cholestasis	technical (choledocho-duodenostomy anatomy)	normal	follow-up
14	Cholestasis	duodenal diverticulum	PSC	follow-up
15	Cholestasis	technical	PSC	follow-up
16	Obstructive jaundice	duodenal diverticulum	normal	follow-up
17	Recurrent pancreatitis	technical	normal	follow-up
18	Recurrent pancreatitis	technical	normal	follow-up
19	Obstructive jaundice	Billroth II anatomy	intrapancreatic stricture of CBD, chronic pancreatitis	choledochoenterostomy cholecystectomy
20	Cholestasis	technical	mild CBD dilation	follow-up
21	Obstructive jaundice	duodenal stenosis	intrapancreatic stricture of CBD, chronic pancreatitis	follow-up
22	Cholestasis	Billroth II anatomy	normal	follow-up

CBD: common bile duct; PSC: primary sclerosing cholangitis; PTD: percutan transhepatic drainage.

Figure 4 Normal Wirsung duct and bilateral renal cysts in an 81-year-old female patient. The intraluminal focus with low signal intensity in the distal common bile duct (arrow) proved to be cholangiocarcinoma. The biliary tree is dilated. With regard to her age and physical status, the

patient underwent biliary stent implantation to ensure bile flow. A: B:



DISCUSSION

ERCP is the most sensitive and specific technique currently available for visualization of the biliary tree and pancreatic duct. Beside the establishment of a diagnosis, this examination at the same time offers therapeutic options. However, ERCP is invasive, and may be associated with complications, and patients who undergo ERCP need sedation. Another disadvantage is that it affords no information on extraductal lesions, and does not opacify the obstructed segment in the event of total duct obstruction. It was unsuccessful in 3-10% of the cases, even in the largest endoscopic centers^[5-7]. Inexperience of the endoscopist and anatomic factors such as previous gastroentero-anastomosis, duodenal stenosis, or periampullary diverticulum might lead to higher rates of unsuccessful ERCP^[19,20]. When the papilla of Vater is in the visual field of the duodenoscope, but conventional cannulation fail, precut papillotomy could be performed with a needle knife, and cannulation could subsequently be achieved. However, precut papillotomy could increase the frequency and severity of complications as compared with conventional ERCP (6-12% vs 1-5%)^[21,22]. Iv cholangiography or PTC examinations are the alternative choices for visualization of the biliary tree. However, iv cholangiography has been no longer used, because its diagnostic accuracy was limited^[8]. PTC is a sensitive method of detecting biliary abnormalities, but it was invasive, might be associated with severe complications, and could successfully be applied if the intrahepatic biliary tree was dilated. In addition, neither PTC nor iv cholangiography was able to visualize the pancreatic duct^[9,10].

The need for a safe and noninvasive technique for examination of the biliary tree and pancreatic duct resulted in the development of MRCP. A number of studies have demonstrated that the sensitivity, specificity, positive and negative predictive values and diagnostic accuracy of MRCP in the detection of biliopancreatic diseases are as high as those of ERCP^[12-16]. Despite

these data, the actual role of MRCP in the diagnostic work-up of patients with suspected biliopancreatic disease is not clear. Besides its advantages, MRCP has certain drawbacks. Most importantly, it does not allow simultaneous therapeutic intervention. While ERCP offers a therapeutic option in the same session after the diagnosis is made (papillotomy, removal of choledocholithiasis, stenting of a biliary stricture, etc.), MRCP yields only the diagnosis. Clips, stents, pneumobilia, hemobilia and ascites might result in artifacts and impede interpretation of the MRCP image. Despite the new technological advances in MR imaging, its resolution has remained behind that of ERCP^[23].

In the present study we assessed the value of MRCP in the management of patients in whom ERCP was unsuccessful. MRCP prevented an invasive procedure in 15 of 22 cases and guided therapy in the remaining 7. Ten patients were treated conservatively. They did not require further diagnostic examinations or therapeutic interventions; they were asymptomatic or responded well to the medical therapy during the follow-up. In 7 patients, therapeutic intervention was indicated by the MRCP findings. The information provided by MRCP was sufficient for the decision-making, and a further diagnostic work-up was required in only 1 patient. This patient (No. 10) was referred to the endoscopy unit because of obstructive jaundice. Duodenoscopy revealed an enlarged papilla of Vater with an irregular surface, which was suspicious of malignancy. Cannulation of the biliary or the pancreatic duct was impossible, even after precut papillotomy. The histological examination of the biopsy specimens taken from the papilla indicated no malignancy. MRCP demonstrated a dilated biliary tree with a severe prepapillary stricture (Figure 1). The pancreas was not separated well from its surroundings in the conventional axial plane MR images, because of the lack of peripancreatic fatty tissue. The Wirsung duct was not depicted or could not be identified among the fluid-filled bowels, despite the use of secretin. The evaluation of the MR images was hampered by the technical artifacts. These findings and the clinical picture together suggested pancreatic head carcinoma. The patient was operated on. The surgery confirmed the suspicion, but a curative resection was impossible as a result of the local invasiveness of the tumor. Biliary-enteric anastomosis was performed.

The sensitivity, specificity, positive and negative predictive values and diagnostic accuracy of MR imaging in the detection of pancreatic cancer were at least as high as those of computer tomography or ERCP^[24,25]. The combination of conventional MR imaging with MRCP and MR

angiography could increase the accuracy in the diagnosis, the staging of pancreatic malignancies and the assessment of respectability^[26-29]. With this combined MR imaging technique, the biliary tree and pancreatic duct with the surrounding vessels and parenchymatous organs could be depicted in one examination, which makes it cost-effective. In our case, the poor quality of the MR imaging with significant amount of artifacts might explain why it was unable to diagnose the cause of the biliary obstruction.

Four patients underwent surgery without further diagnostic examinations. In 3 cases the diagnosis made by MR was confirmed by the surgical findings. In 1 case (No. 10), the MR revealed only the site, but not the cause (i.e. pancreatic cancer) of the bile duct obstruction, which was diagnosed during the operation. In 3 patients, surgery was not recommended because of their moribund physical status. PTC was performed and in each case confirmed the results of MRCP. These patients subsequently underwent biliary drainage.

Seven out of 22 patients required intervention after MRCP. This points the major drawbacks of MRCP. It is unable to combine therapy with diagnosis. It could be argued that the 3 patients with obstructive jaundice who required PTC and PTD after MRCP might have better served by proceeding to this modality directly. However, the fact that MRCP is noninvasive is a powerful point in its favor. It can identify those patients where therapeutic intervention is needed.

Our results suggest that MRCP is a feasible and valuable diagnostic modality in patients in whom ERCP fails. MRCP facilitates the management of these patients. It differentiates patients who require invasive therapy from those who can be treated conservatively, and provides information necessary for the planning of surgical or radiological interventions.

REFERENCES

- 1 Pasanen PA, Partanen KP, Pikkarainen PH, Alhava EM, Janatuinen EK, Pirinen AE. A comparison of ultrasound, computed tomography and endoscopic retrograde cholangiopancreatography in the differential diagnosis of benign and malignant jaundice and cholestasis. *Eur J Surg* 1993; 159: 23-29
- 2 Ponchon T, Pilleul F. Diagnostic ERCP. *Endoscopy* 2002; 34: 29-42
- 3 Baron TH, Fleischer DE. Past, present, and future of endoscopic retrograde cholangiopancreatography: perspectives on

- the National Institutes of Health consensus conference. Mayo Clin Proc 2002; 77: 407-412
- 4 NIH State of Science Conference on ERCP. 2002-01-14-16. Available from: URL:
<http://consensus.nih.gov>
- 5 Bilbao MK, Dotter CT, Lee TG, Katon RM. Complications of endoscopic retrograde
cholangiopancreatography (ERCP). A
study of 10 000 cases. Gastroenterology 1976; 70: 314-320
- 6 Choudari CP, Sherman S, Fogel EL, Phillips S, Kochell A, Flueckiger J, Lehman GA.
Success of ERCP at a referral center
after a previously unsuccessful attempt. Gastrointest Endosc 2000; 52: 478-483
- 7 Loperfido S, Angelini G, Benedetti G, Chilovi F, Costan F, De Berardinis F, De Bernardin
M, Ederle A, Fina P, Fratton A.
Major early complications from diagnostic and therapeutic ERCP: a prospective multicenter
study. Gastrointest Endosc
1998; 48: 1-10
- 8 Tham TC, Collins JS, Watson RG, Ellis PK, McIlrath EM. Diagnosis of common bile duct
stones by intravenous
cholangiography: prediction by ultrasound and liver function tests compared with endoscopic
retrograde
cholangiography. Gastrointest Endosc 1996; 44: 158-163
- 9 Ott DJ, Gelfand DW. Complications of gastrointestinal radiologic procedures: II.
Complications related to biliary tract
studies. Gastrointest Radiol 1981; 6: 47-56
- 10 Harbin WP, Mueller PR, Ferrucci JT Jr. Transhepatic cholangiography: complications and
use patterns of the fine-needle
technique: a multi-institutional survey. Radiology 1980; 135: 15-22
- 11 Soto JA, Yucel EK, Barish MA, Chuttani R, Ferrucci JT. MR cholangiopancreatography
after unsuccessful or incomplete
ERCP. Radiology 1996; 199: 91-98
- 12 Lomanto D, Pavone P, Laghi A, Panebianco V, Mazzocchi P, Fiocca F, Lezoche E,
Passariello R, Speranza V. Magnetic
resonance-cholangiopancreatography in the diagnosis of biliopancreatic diseases. Am J Surg

1997; 174: 33-38

13 Coakley FV, Schwartz LH. Magnetic resonance cholangiopancreatography. J Magn Reson Imaging 1999; 9: 157-162

14 Takehara Y. Can MRCP replace ERCP? J Magn Reson Imaging 1998; 8: 517-534

15 Soto JA, Barish MA, Yucel EK, Siegenberg D, Ferrucci JT, Chuttani R. Magnetic resonance cholangiography: comparison with endoscopic retrograde cholangiopancreatography. Gastroenterology 1996; 110: 589-597

16 Sahai AV, Devonshire D, Yeoh KG, Kay C, Feldman D, Willner I, Farber J, Patel R, Tamasky PR, Cunningham JT, Trus T, Hawes RH, Cotton PB. The decision-making value of magnetic resonance cholangiopancreatography in patients seen in a referral center for suspected biliary and pancreatic disease. Am J Gastroenterol 2001; 96: 2074-2080

17 Czako L, Endes J, Takacs T, Boda K, Lonovics J. Evaluation of pancreatic exocrine function by secretin-enhanced magnetic resonance cholangiopancreatography. Pancreas 2001; 23: 323-328

18 Hellerhoff KJ, Helmberger H 3rd, Rosch T, Settles MR, Link TM, Rummeny EJ. Dynamic MR pancreatography after secretin administration: image quality and diagnostic accuracy. Am J Raentgenol 2002; 179: 121-129

19 Nicaise N, Pellet O, Metens T, Deviere J, Braude P, Struyven J, Matos C. Magnetic resonance cholangiopancreatography: interest of IV secretin administration in the evaluation of pancreatic ducts. Eur Radiol 1998; 8: 16-22

20 Mosca S. How can we reduce complication rates and enhance success rates in Billroth II patients during endoscopic retrograde cholangiopancreatography? Endoscopy 2000; 32: 589-590

21 Rollhauser C, Al-Kawas FH. Endoscopic access to the papilla of Vater for endoscopic retrograde cholangiopancreatography in patients with Billroth II or Roux-en-Y gastrojejunostomosis. Gastrointest Endosc

1997; 46: 581-582

22 Larkin CJ, Huibregtse K. Precut sphincterotomy: indications, pitfalls, and complications. *Curr Gastroenterol Rep*

2001; 3: 147-153

23 Keogan MT, Edelman RR. Technological advances in abdominal MR imaging. *Radiology* 2001; 220: 310-320

24 Adamek HE, Albert J, Breer H, Weitz M, Schilling D, Riemann JF. Pancreatic cancer detection with magnetic resonance

cholangiopancreatography and endoscopic retrograde cholangiopancreatography: a prospective controlled study.

Lancet 2000; 356: 190-193

25 Ichikawa T, Haradome H, Hachiya J, Nitatori T, Ohtomo K, Kinoshita T, Araki T.

Pancreatic ductal adenocarcinoma:

Preoperative assessment with helical CT versus dynamic MR imaging. *Radiology* 1997; 202: 655-662

26 Catalano C, Pavone P, Laghi A, Panebianco V, Scipioni A, Fanelli F, Brillo R, Passariello R. Pancreatic adenocarcinoma:

combination of MR imaging, MR angiography and MR cholangiopancreatography for the diagnosis and assessment of

resectability. *Eur Radiol* 1998; 8: 428-434

27 Adamek HE, Breer H, Karschkes T, Albert J, Riemann JF. Magnetic resonance imaging in gastroenterology: time to say

good-bye to all that endoscopy? *Endoscopy* 2000; 32: 406-410

28 Mitchell RM, Byrne MF, Baillie J. Pancreatitis. *Lancet* 2003; 361: 1447-1455

29 Kay CL. Which test to replace diagnostic ERCP - MRCP or EUS? *Endoscopy* 2003; 35: 426-428

Edited by Wang XL Proofread by Chen WW and Xu FM